



The use of magnets with single-site umbilical laparoscopic surgery

Benjamin E. Padilla, MD, Guillermo Dominguez, MD, Carolina Millan, MD, Marcelo Martinez-Ferro, MD

From the Department of Surgery, Fundacion Hospitalaria Children's Hospital, Buenos Aires, Argentina.

KEYWORDS

Magnet;
Laparoscopic;
Children;
Minimally invasive;
Single-site umbilical
incision laparoscopic
surgery;
SSULS

Single-site umbilical incision laparoscopic surgery (SSULS) is increasingly being used to treat a variety of childhood surgical diseases. Existing SSULS approaches have inefficient triangulation and poor ergonomics. In an effort to overcome these shortcomings, magnet-assisted laparoscopy was developed. Specialized magnetic graspers are introduced through a standard 12-mm port and are controlled by a powerful external magnet. This study is a retrospective analysis of all magnet-assisted laparoscopic operations performed at the Fundacion Hospitalaria Private Children's Hospital from September 2009 to January 2011. Outcomes include demographics, diagnosis, operative time, intraoperative complications, and conversion rates. Forty-four magnet-assisted laparoscopic operations were performed. The operations included 23 appendectomies, 8 cholecystectomies, 3 Nissen funduplications, 2 gastrojejunostomies, 2 splenectomies, 2 ovarian tumor/cyst resections, 1 retroperitoneal lymphangioma resection, 1 left adrenalectomy, 1 total abdominal colectomy and 1 pulmonary wedge resection. The mean operative times for the most commonly performed operations were 61 minutes for appendectomy and 93 minutes for cholecystectomy. The operations were classified as follows: Group I, adjunct to conventional laparoscopy (5 operations); Group II, adjunct to multiple-access umbilical laparoscopy (11 operations); and Group III, true single-port laparoscopy (28 operations). Among Group II/III operations, 6 operations required 1 additional port outside the umbilicus. No operations required more than 1 additional port, and no operations were converted to the open technique. There were no intraoperative complications. Magnet-assisted laparoscopic surgery is safe and effective in children. The use of magnetic graspers improves triangulation and ergonomics while reducing the number and size of abdominal incisions.

© 2011 Elsevier Inc. All rights reserved.

Laparoscopic surgery has supplanted open surgery as the standard of care for many clinical conditions because it results in decreased pain, faster recovery, and less scarring. In an effort to further minimize the invasiveness of these operations, surgeons are now operating through a single incision through which all the instruments are placed.^{1–4}

Most commonly, the single incision is made in the umbilicus, and instruments are introduced either through a single specialized port or multiple small fascial incisions. So-called single-site umbilical laparoscopic surgery (SSULS) and its variations have the same shortcomings: poor triangulation of the instruments and telescope, instrument collision, and lack of maneuverability and reach.

Magnet-assisted laparoscopic surgery was developed to recapture the triangulation that is afforded by conventional laparoscopy while decreasing the number and size of the abdominal incisions. Specialized magnetic graspers (Dominguez

Address reprint requests and correspondence: Marcelo Martinez-Ferro, MD, Department of Surgery, Fundacion Hospitalaria Children's Hospital, Cramer 4601 Third Floor, C1429AKK, Buenos Aires, Argentina.
E-mail: martinezferro@fibertel.com.ar.

Magnetic Grasper [DMG]; IMANLAP, Buenos Aires, Argentina) are inserted into the peritoneal cavity through a 12-mm cannula and are attached to an intraabdominal organ and are controlled by powerful external magnets. By repositioning the external magnet on the abdominal wall, the intraabdominal magnet moves to provide further traction on an organ (gallbladder, appendix). Because the magnet is not fixed at the level of the fascia, it can freely cruise around the peritoneal cavity, extending the surgeon's reach without the need for additional ports.

Magnet-assisted laparoscopic surgery has been used in a range of operations in adults and has proven to be safe and effective.^{5,6} Introduction of this magnetic platform into our surgical armamentarium has altered our approach to conventional laparoscopy and has allowed us to perform true single-port laparoscopic surgery. Herein we describe our experience with the use of magnet-assisted laparoscopic surgery in children.

Specialized equipment

In addition to standard laparoscopic equipment, magnet-assisted laparoscopic surgery requires several specially designed instruments. The DMG is a spring-loaded alligator grasper attached to an 11-mm neodymium magnet (Figure 1A). The DMG is coupled to a powerful external magnet by

magnetic forces transmitted across the abdominal wall. To grasp tissue, the jaws of the DMG are opened and closed with 5-mm Thomas forceps made of austenitic surgical steel that is not affected by the magnetic field (Figure 1B). Once the DMG is engaged, repositioning the external magnet on the abdominal wall controls the DMG. Varying the distance between the DMG and the external magnet modulates the force that is transmitted to the DMG. To free the surgeon's hands for other tasks, the external magnet is mounted on an articulating self-retaining arm that can be easily repositioned during the operation (Figure 1C).

In general, a single 12-mm cannula is needed because it accommodates the 11-mm DMG. However, operations requiring more extensive dissection or intraabdominal suturing are undertaken with a Single-Incision Laparoscopic Surgery (SILS) port (Covidien, Mansfield, MA). We prefer to use an operative laparoscope because it allows the surgeon to operate and drive the camera simultaneously. Furthermore, the operative laparoscope fixes visualization at the point of dissection without the need for cumbersome roticulating instruments. We use a 10-mm, 0° laparoscope with a 27-cm long, 6-mm working channel (Figure 2A; Karl Storz, Tuttlingen, Germany). Although the operative laparoscope accommodates commercially available 5-mm × 42-cm instruments, we have lengthened the Thomas forceps and 5 mm Hem-o-Lock clip applier to allow them to be inserted through the scope. We find most existing SSULS instru-

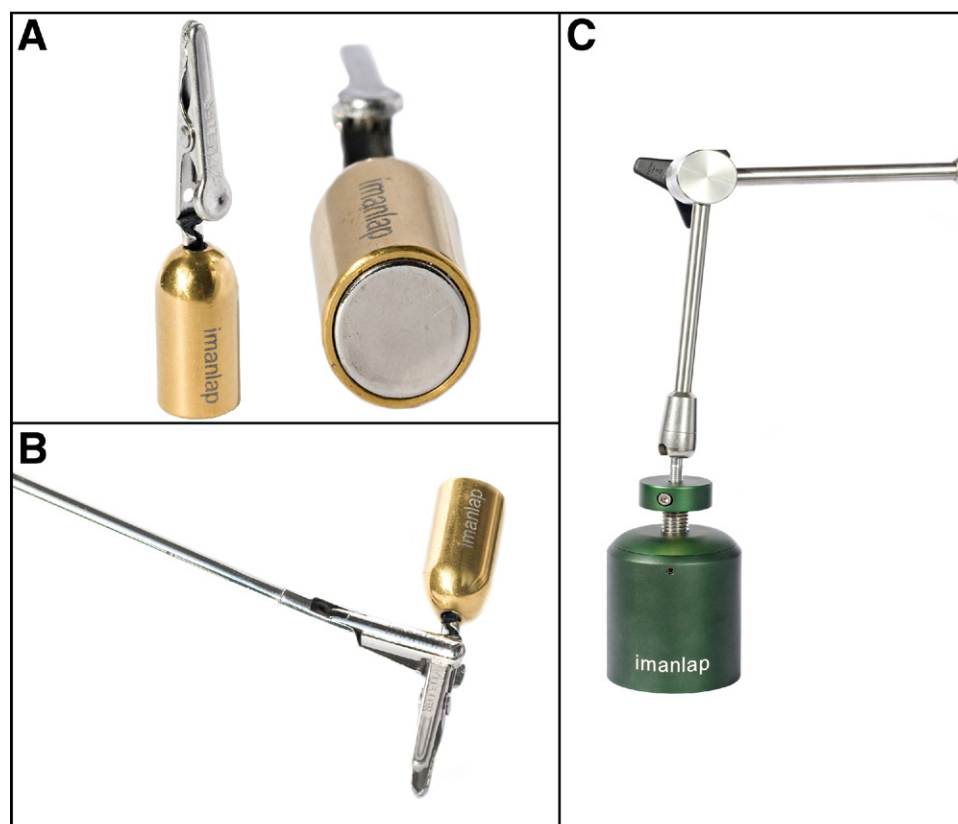


Figure 1 (A) Dominguez Magnetic Graspers (DMG). (B) Thomas forceps are used to open the jaws of the DMG. (C) External magnet mounted on self-retaining retractor. (Color version of figure is available online.)

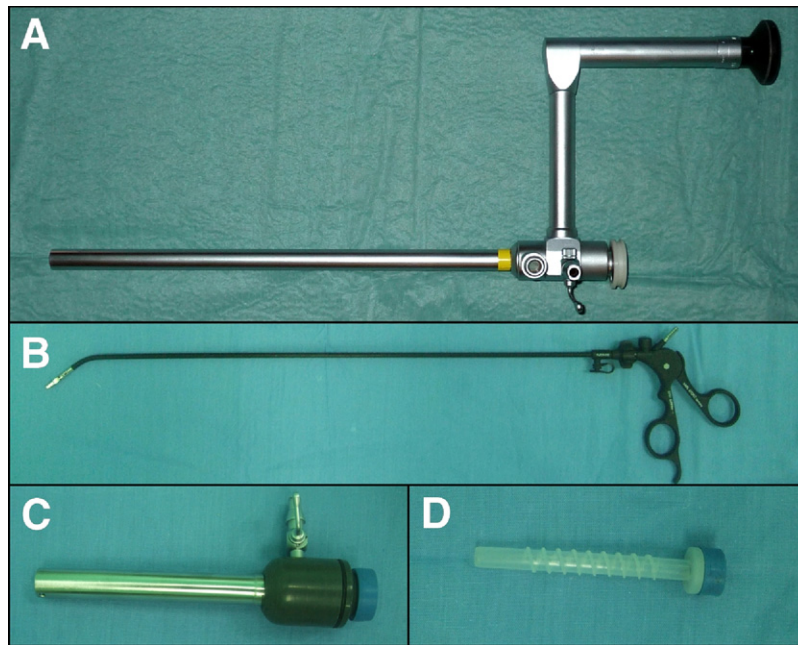


Figure 2 (A) 10 mm, 0° operative laparoscope with 6 mm working channel. (B) Gently curved, roticulating grasper used in multiple-access transumbilical laparoscopy. (C) Primary 12-mm umbilical port. (D) The 5-mm, flexible accessory cannula accommodates the curved grasper. (Color version of figure is available online.)

ments with exaggerated curves or roticulating tips impractical because they transmit little torque and their movements are counterintuitive. Thus, we prefer a 5-mm gently curved, nonroticulating grasper (Figure 2B; Karl Storz, Tuttlingen, Germany).

Operative technique

By using the magnets, our goal is to reduce the number and size of abdominal incisions. Rather than adopting a one-size-fits-all approach to SSULS operations, we sought to incorporate magnet-assisted laparoscopic surgery into a broad range of operations. As such, operations could be grouped into 3 general categories: adjunct to conventional laparoscopic surgery,

adjunct to multiple-access umbilical laparoscopic surgery, and true single-port laparoscopic surgery.

Adjunct to conventional laparoscopic surgery: reducing the number of ports

We have used magnetic graspers in laparoscopic gastrojejunostomy and Nissen fundoplication, as well as thoracoscopic pulmonary wedge resection, with the objective of reducing the number of ports needed to complete the operations. The DMG grasped and aligned the stomach with the jejunum as the Endo GIA (Covidien) was inserted to create the gastrojejunostomy (Figure 3). In the Nissen fundoplication, the DMG was used to retract the liver and stomach and also proved useful in assisting with laparoscopic knot-tying.

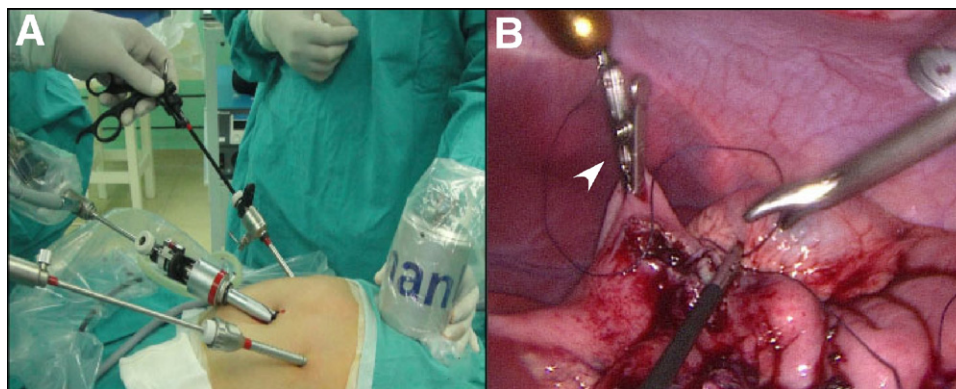


Figure 3 Group I- Adjunct to conventional laparoscopic surgery. (A) The external magnet on the epigastrium controls the DMG during a laparoscopic gastrojejunostomy. (B) The DMG (arrowhead) retracts the stomach as the gastrojejunostomy is sutured closed. (Color version of figure is available online.)

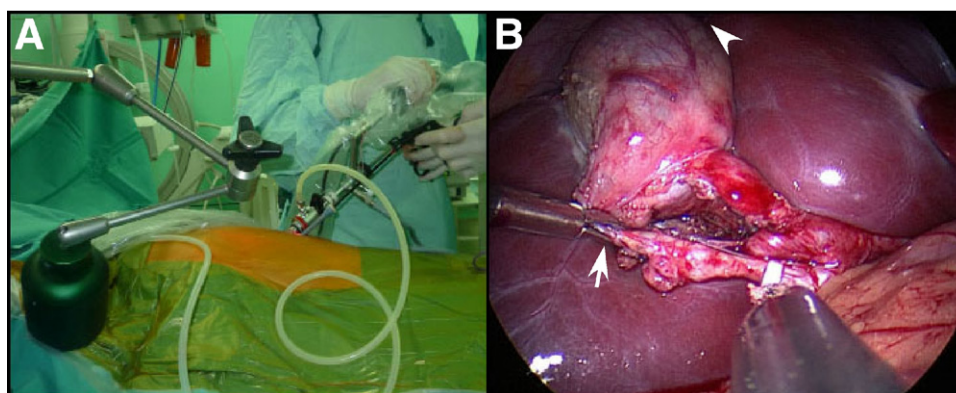


Figure 4 Group II- Adjunct to multiple-access transumbilical laparoscopic surgery. (A) Magnet-assisted cholecystectomy with the 5- and 12-mm cannulas in a single umbilical incision. (B) The DMG (arrowhead) elevates the gallbladder fundus above the liver edge and the curved grasper (arrow) opens the triangle of Calot as the dissection is performed through the operative laparoscope. (Color version of figure is available online.)

More recently we have used the DMG to provide traction on the lung and feed the lung tissue into the jaws of the Endo-stapler. In the patient who underwent the thoracoscopic lung biopsy, the DMG was inserted through the same 12-mm cannula that was later used to introduce the endoscopic stapler. A 5-mm cannula served as the camera port.

Adjunct to multiple-access umbilical laparoscopic surgery

We have used 2 types of multiple-access umbilical approaches. In the first, a 12-mm cannula and 5-mm low profile port were introduced through the umbilical fascia within the same skin incision. Operations performed by this technique have included adrenalectomy, cholecystectomy, ovarian cystectomy, mesenteric lymphangioma resection, and ovarian teratoma resection. During cholecystectomies, the DMG has provided enough force to retract the fundus of the gallbladder over the liver edge toward the patient's right shoulder (Figure 4). In the other operations, a single DMG provided traction and facilitated exposure. Generally, the gently

curved, nonroticulating grasper provided countertraction through the 5-mm port and the dissection was performed through the working channel on the operative laparoscope which was introduced through the 12-mm cannula.

The second technique used a SILS port inserted at the umbilicus. Operations that used this approach included cholecystectomy, splenectomy, total abdominal colectomy (Figure 5), and Nissen fundoplication. A single DMG provided traction and exposure in these operations. We prefer to use the operative laparoscope because it reduces the number of instruments inserted through the port, thus reducing instrument collision. However, a 5-mm, 30° laparoscope and two 5-mm instruments were used in operations that required intracorporeal suturing.

True single-port laparoscopic surgery

We defined true single-port laparoscopic surgery as an abdominal operation that uses one standard 12-mm cannula at the umbilicus without any additional ports or stay sutures penetrating the fascia. Magnet-assisted appendectomies and

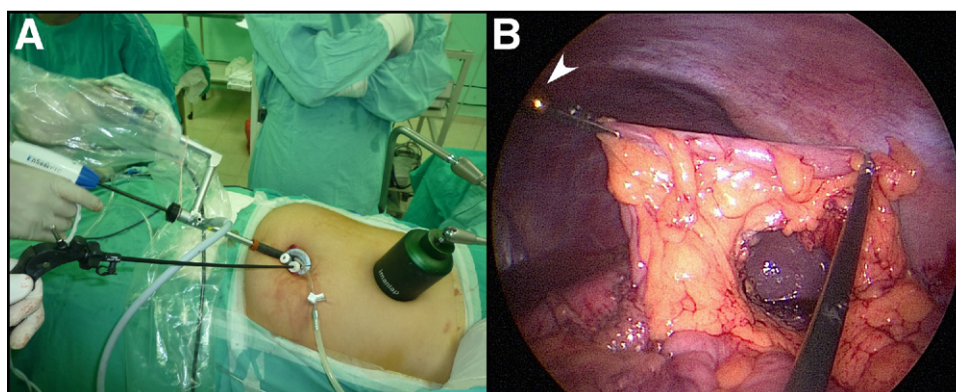


Figure 5 Group II- Adjunct to multiple-access transumbilical laparoscopic surgery. (A) Magnet-assisted abdominal colectomy utilizing a SILS port. The magnet is resting on the lower abdomen. (B) The DMG (arrowhead) provides traction on the left colon as the mesentery is transected. (Color version of figure is available online.)

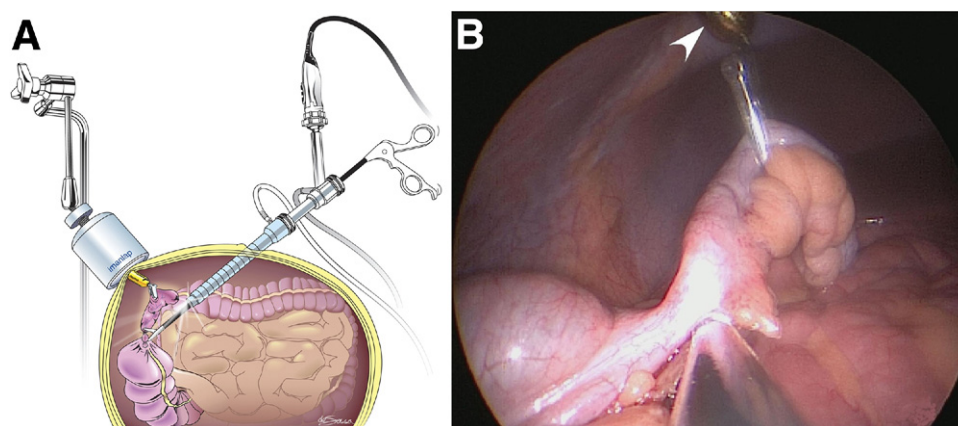


Figure 6 Single port magnet-assisted appendectomy. This schematic (A) depicts the DMG retracting on the appendix. On the right (B), the operative photograph shows the DMG (arrowhead) retracting the appendix as the mesoappendiceal dissection is performed through the operative laparoscope. (Color version of figure is available online.)

cholecystectomies have been performed with this approach. Appendectomies were performed intracorporeally with the operative laparoscope and a single DMG (Figure 6). The DMG was attached to the appendix and provided traction as the mesoappendix was transected with a 5-mm Ligasure device (Covidien). Next, the base of the appendix was doubly ligated with either 3-0 chromic sutures or 5-mm Hem-o-Lock (Teleflex Medical, Research Triangle Park, NC) clips and then transected. The appendix was removed through the umbilical trocar to minimize wound contamination.

Single-port cholecystectomy required 2 DMGs, one placed on the fundus of the gallbladder and the other on the infundibulum (Figure 7). Each DMG was coupled to a separate external magnet to provide traction in different directions. The use of 2 DMGs provided excellent exposure of the triangle of Calot. However, extra attention was needed to avoid bringing the 2 DMGs into close proximity as the magnetic force tended to “clump” the 2 DMGs together. The dissection was performed with the operative laparoscope and electrocautery. Once the critical view of

safety was achieved, the cystic duct and artery were doubly ligated with 5-mm Hem-o-Lock clips and transected. The gallbladder was dissected away from the gallbladder fossa and removed through the umbilical incision.

Results

A total of 44 magnet-assisted laparoscopic operations in 43 patients (16 boys and 27 girls) have been performed between September 2009 and January 2011. This experience includes 23 appendectomies, 8 cholecystectomies, 3 Nissen funduplications, 2 gastrojejunostomies, 2 splenectomies, 2 ovarian teratoma resections, 1 mesenteric lymphangioma resection, 1 total abdominal colectomy for familial adenomatous polyposis, 1 left adrenalectomy for pheochromocytoma, and 1 pulmonary wedge resection for bullous disease. The mean age was 12.5 years (range, 4-24 years) and mean weight was 45.8 kg (range, 15-107 kg). The overall mean operative time for the most commonly performed operations

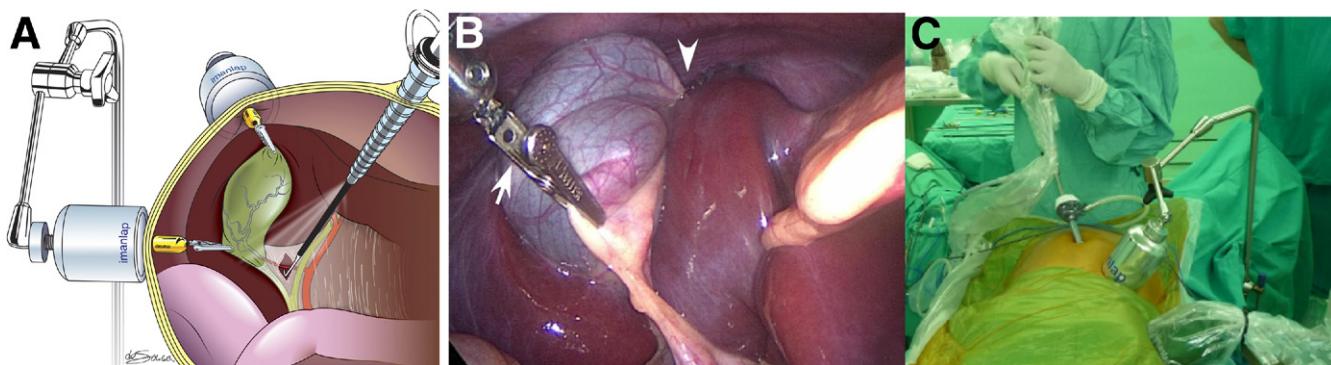


Figure 7 Single port magnet-assisted cholecystectomy. In the drawing (A), two DMGs retract the gallbladder and open the triangle of Calot while the dissection is performed through the operative laparoscope. In the operative photograph (B), two DMGs are providing traction on the fundus (arrowhead) and infundibulum (arrow). The external view (C) shows the two external magnets controlling their intra-abdominal DMGs during the SSULS cholecystectomy. (Color version of figure is available online.)

Table 1 Summary of magnet-assisted laparoscopic operations

	<i>n</i>	Age, years	Weight, kg	Operative time, min	Umbilical access	Total # of trocars (includes umbilical)
<i>Group I: Adjunct to conventional laparoscopic surgery</i>						
Gastrojejunostomy*	2	7	XX	150	4 mm	3
Nissen fundoplication*	2	8	22	105	12 mm	3
Pulmonary wedge resection	1	15	50	65	12 mm + 5 mm (thoracic)	2
<i>Group II: Adjunct to multiple-access umbilical laparoscopic surgery</i>						
Nissen fundoplication	1	13	35	180	SILS port	4 (3 via SILS)
Total abdominal colectomy	1	15	107	420	SILS port	4 (3 via SILS)
Cholecystectomy + splenectomy	1	5	24	180	SILS port	3 (all via SILS)
Splenectomy	1	12	31	150	12 mm + 5 mm	2
Left adrenalectomy	1	24	70	180	12 mm + 5 mm	3
Retroperitoneal lymphangioma resection	1	9	50	60	12 mm + 5 mm	2
Cholecystectomy*	2	17	50	85	12 mm + 5 mm	2
Ovarian cyst/tumor resection*	2	16.2	62.5	95	12 mm + 5 mm	2
<i>Group III: True single-port laparoscopic surgery</i>						
Cholecystectomy*	5	14.8	43.8	96	12 mm	1
Appendectomy*	23	12.23	46.5	61	12 mm	1

*Values expressed as mean for the group, exceptions to port placement listed in Table 2.

was 61 minutes (range, 20-105 min) for appendectomy and 93 minutes (range, 50-150 min) for cholecystectomy. There were no intraoperative complications.

Magnetic graspers were used in 5 operations that were otherwise performed with the use of conventional laparoscopic techniques. Thus, 39 operations were performed via the transumbilical approach and includes patients from both groups II and III (Table 1). True single-port operations, group III, included 23 appendectomies and 6 cholecystectomies. Six (15%) of these 39 operations required the use of one additional port to complete the operation. These include 3 appendectomies, 1 cholecystectomy, 1 colectomy, and 1 adrenalectomy (Table 2). No operations were converted to an open approach.

Discussion

Our experience shows that magnet-assisted laparoscopy in children is a safe and effective means of reducing the number and size of abdominal incisions while improving exposure, triangulation, and the ergonomics of the operation. Incorporating magnets into our surgical strategy has altered our approach to a broad range of operations. The use of magnetic graspers as an adjunct to conventional laparoscopic surgery reduces the number of ports without fundamentally altering how the operation is performed. Thus, the technology can readily be incorporated into surgical practice without a difficult learning curve. As an adjunct to multiple-access umbilical surgery, magnetic graspers not only improve triangulation but also decrease the number of instruments entering at the umbilicus. This ameliorates the most commonly cited problem with existing SSULS techniques which is cannula crowding, instrument collision, and hand crossing.¹ Furthermore, the use of magnets allows for true single-port surgery for routine operations, such as appendectomy and cholecystectomy. This streamlined technique eliminates large or multiple fascial incisions and allows the surgeon to operate and drive the camera simultaneously using the operative laparoscope.

With the exception of cholecystectomies, in most magnet-assisted operations we used a single DMG. In our experience, a capable laparoscopic surgeon can quickly learn to deploy and control a single DMG. However, there is a longer learning curve for the use of multiple DMGs because the DMGs tend to “clump” together if they are brought close to one another. If 2 DMGs are used, we find that tethering the second DMG to a prolene suture helps to separate the DMGs should they clump together. Our preference is to use 2 DMGs for cholecystectomies, one at the fundus and the other at the infundibulum, because this

Table 2 Transumbilical operations (Groups II and III) requiring additional ports

Port	Number/type of port	Indication for additional port
Nissen fundoplication	1;5 mm	Needed for Intraperitoneal Suturing
Total abdominal colectomy	1;12 mm	Needed for Endo-GIA to transect rectum
Left adrenalectomy	1;5 mm	Needed for difficult dissection
Appendectomy	1;5 mm	Retrocecal appendix, difficult dissection
Appendectomy	1;5 mm	Perforated, gangrenous appendicitis
Appendectomy	1;5 mm	Long, tortuous appendix, difficult dissection

allows the surgeon to perform the operation alone. However, initially a novice surgeon to this technology might be better served using a single DMG at the gallbladder fundus and a 5-mm grasper to manipulate the infundibulum.

SSULS is becoming increasingly common in the pediatric population. Hansen et al¹ recently reported a series of 224 SSULS cases in children. Overall, 21% of the operations required at least one additional port. When considering commonly performed operations, additional ports were required in 15% of appendectomies (18 of 122) and 72% of cholecystectomies (23 of 32) in this series. Our results are similar as an additional cannula was required in 13% of our magnet-assisted appendectomies (3 of 23), but none of our magnet-assisted cholecystectomies (0 of 8). The need for additional ports is a reflection of poor exposure and triangulation. Rather than placing an additional port and instrument, other groups use transabdominal sutures placed through the abdominal wall and then through the gallbladder fundus or appendix to provide traction.^{4,7} We have abandoned the use of traction sutures with the development of the DMG because these sutures can result in intraabdominal spillage of bile, gallstones, or pus. Furthermore, we are concerned that the suture tract is a potential site for infection. We use the DMG to grasp the gallbladder directly and, to date, have not had any problems with perforating the gallbladder.

There were no intraoperative complications in the present series. In a prior report in which the authors used this technology in adults, the DMG was dropped in the abdominal cavity and required fluoroscopy to retrieve the DMG.⁶ In our experience, when the DMG is dropped in the abdominal cavity, it was easily brought to the abdominal wall by use of the external magnet. The DMG did not cause any pressure necrosis of the abdominal wall that we could see. The use of a different system of magnetically coupled instruments in animals, Best et al⁸ showed that there was no gross or microscopic pressure necrosis of the abdominal wall. Furthermore, the presence of a powerful magnetic field did not interfere with any electronic surgical equipment or anesthesia monitors nor did it have untoward effects on patient physiology.

Other groups are exploring the use of magnetically controlled instruments in laparoscopic surgery. Best and Cadeddu⁹ recently described their experience with magnet anchoring and guidance systems (MAGS). MAGS uses external magnets to stabilize a base plate against the peritoneal surface of the abdominal wall. Instruments, such as a fan retractor, remote controlled electrocautery, and wireless video camera are mounted on the base plate and controlled by repositioning the platform. This technology has shown promise in porcine models in which single-port and natural orifice transluminal endoscopic surgery (ie, NOTES) cholecystectomies and nephrectomies have been performed.¹⁰⁻¹² Although the experience with MAGS in humans is much more limited, Cadeddu et al¹³ has described the use of the MAGS video camera to

good effect in one SSULS appendectomy and one SSULS nephrectomy. Unlike the DMG that can be readily repositioned to grasp tissue in a different location, MAGS and other magnetic graspers under development are fixed to tissue with an Endoclip, making repositioning difficult and time-consuming.¹⁴ Kume et al¹⁵ report a novel application of magnets that are anchored in the bowel lumen and provide traction via an external magnet. This technique has been used in a swine proctectomy model but is limited by the fact that proctoscopy is required to place and reposition the intraluminal magnet. Another promising application for magnets is the development of magnetically guided, wireless endocameras.¹⁶

A potential drawback of magnet-assisted laparoscopic surgery is that it requires specialized magnetic instruments that are not widely available at present. In addition, performing true single port operations requires a dedicated operative laparoscope and extralong 5-mm laparoscopic instruments. Other authors^{3,4,17} report the use of a 20-cm Frazee operative laparoscope that may be a better alternative because standard 36-cm long laparoscopic instruments can be used. Although the operative laparoscope is widely used in other surgical disciplines, pediatric surgeons have been reluctant incorporate it into practice citing problems with visualization at the tip of the instrument. We find that visualization can be optimized by maintaining a short working length between the end of the telescope and tip of the instrument. Although some authors place retraction instruments through the operative laparoscope, our preference is to insert the dissecting instrument through the scope, thus fixing visualization at the point of dissection.

In conclusion, our experience shows that magnet-assisted laparoscopy can be safely and effectively incorporated into surgical practice in children. Although this technology can be readily applied as an adjunct to conventional laparoscopy, it also allows a means for performing true single port laparoscopic surgery.

References

1. Hansen EN, Muensterer OJ, Georgeson KE, et al. Single-incision pediatric endosurgery: Lessons learned from our first 224 laparoendoscopic single-site procedures in children. *Pediatr Surg Int* 2011;27:643-8.
2. Garey CL, Laituri CA, Ostlie DJ, et al. A review of single site minimally invasive surgery in infants and children. *Pediatr Surg Int* 2010;26:451-6.
3. Ponsky TA, Diluciano J, Chwals W, et al. Early experience with single-port laparoscopic surgery in children. *J Laparoendosc Adv Surg Tech A* 2009;19:551-3.
4. Rothenberg SS, Shipman K, Yoder S. Experience with modified single-port laparoscopic procedures in children. *J Laparoendosc Adv Surg Tech A* 2009;19:695-8.
5. Davila F, Tsin DA, Dominguez G, et al. Transvaginal cholecystectomy without abdominal ports. *JSLs* 2009;13:213-6.
6. Dominguez G, Durand L, De Rosa J, et al. Retraction and triangulation with neodymium magnetic forceps for single-port laparoscopic cholecystectomy. *Surg Endosc* 2009;23:1660-6.

7. Dutta S. Early experience with single incision laparoscopic surgery: Eliminating the scar from abdominal operations. *J Pediatr Surg* 2009; 44:1741-5.
8. Best SL, Kabbani W, Scott DJ, et al. Magnetic anchoring and guidance system instrumentation for laparo-endoscopic single-site surgery/natural orifice transluminal endoscopic surgery: Lack of histologic damage after prolonged magnetic coupling across the abdominal wall. *Urology* 2011;77:243-7.
9. Best SL, Cadeddu JA. Use of magnetic anchoring and guidance systems to facilitate single trocar laparoscopy. *Curr Urol Rep* 2010;11: 29-32.
10. Raman JD, Bergs RA, Fernandez R, et al. Complete transvaginal NOTES nephrectomy using magnetically anchored instrumentation. *J Endourol* 2009;23:367-71.
11. Raman JD, Scott DJ, Cadeddu JA. Role of magnetic anchors during laparoendoscopic single site surgery and NOTES. *J Endourol* 2009; 23:781-6.
12. Scott DJ, Tang SJ, Fernandez R, et al. Completely transvaginal NOTES cholecystectomy using magnetically anchored instruments. *Surg Endosc* 2007;21:2308-16.
13. Cadeddu J, Fernandez R, Desai M, et al. Novel magnetically guided intra-abdominal camera to facilitate laparoendoscopic single-site surgery: Initial human experience. *Surg Endosc* 2009;23:1894-9.
14. Kume M, Miyazawa H, Abe F, et al. A newly designed magnet-retracting forceps for laparoscopic cholecystectomy in a swine model. *Minim Invasive Ther Allied Technol* 2008;17:251-4.
15. Kume M, Miyazawa H, Iwasaki W, et al. The use of magnetic anchors in the bowel lumen for laparoscopic anterior resection of rectosigmoid colon in pigs: With video. *World J Surg* 2008;32:2425-8.
16. Valdastrì P, Quaglia C, Buselli E, et al. A magnetic internal mechanism for precise orientation of the camera in wireless endoluminal applications. *Endoscopy* 2010;42:481-6.
17. Khosla A, Ponsky TA. Use of operative laparoscopes in single-port surgery: The forgotten tool. *J Minim Access Surg* 2011;7:116-20.